

Treatment of Venous Insufficiency Complicated by Stasis Dermatitis: Less is More Approach Using a Silver Moisture Management Wrap

Kristina Daly; RN, BSN, Anita Robinson; RN, BS, WCC, OMS

Introduction

Chronic venous insufficiency is responsible for 70% of chronic wounds of the lower extremities. (1) Due to the chronic nature of venous insufficiency, skin injury from excessive weeping and drainage result in pruritus and excoriation. The traditional treatment for venous insufficiency ulcers is the use of compression wraps. However, compression wraps introduce other challenges such as managing exudate, protecting the periwound, and proper skin moisturizing. (2, 3) Many of the products used to treat these conditions can cause adverse reactions. The more products used, the more difficult it becomes to establish which products are helping or hurting. (4) Stasis dermatitis is common in venous ulcers, and the elderly population is at an increased risk because rashes, sensitivities, and contact dermatitis are more common among this population. (5)

Methods

In the following cases, Silver Moisture Management wrap 4"x 48" (AFM**) was applied directly to the lower leg. No topical ointments or creams were used. AFM was covered with an absorbent layer and secured with gauze. In each case, the AFM was left in place while the outer dressing was changed once or twice a week either at the clinic or by home health care. Case 1 and 3 had light compression of cotton and cohesive bandage. Case 2 had no compression due to severe arterial disease.

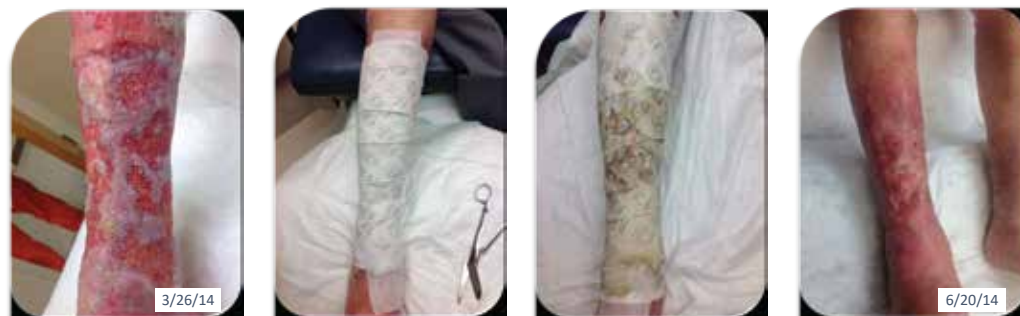Conclusions

In conclusion, Silver Moisture Management wrap (AFM) is an effective treatment for venous stasis ulcers complicated by stasis dermatitis. The moisture wicking action of the AFM dressing decreases constant irritation from wound exudate and minimizes periwound excoriation. Unanticipated benefits include decreased pain, decreased nursing time, and reduction in cost related to supplies and nursing time.

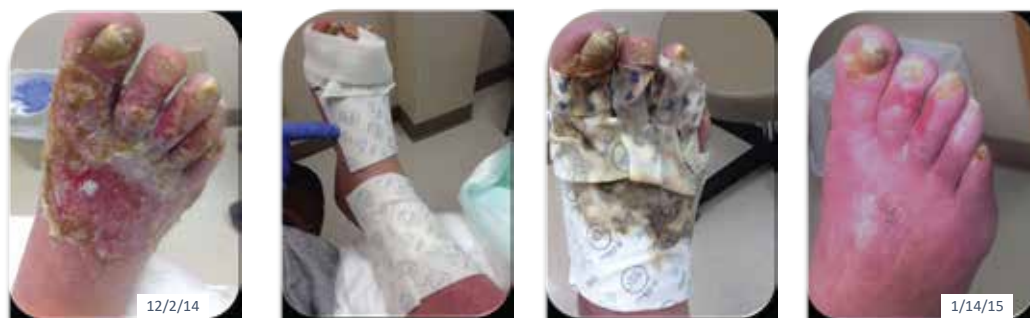References

1. Abbade LP, Lastoria S. Venous ulcer epidemiology, physiopathology, diagnosis, and treatment. *Int J Dermatol*, 2005 Jun; 44(6): 449-56
2. Douglas WS, Simpson NB. Guidelines or the management of chronic venous leg ulceration. Report of multidisciplinary workshop. *British Association of Dermatologists and the Research unit of the Royal College of Physicians. Br J Dermatol* 1995; 132:446.
3. Bolton L, Girolami S, Corbett L, Rijswijk L. The Association for the Advancement of Wound Care (AAWC) Venous and Pressure Ulcer Guidelines. *Ostomy Wound Management*. 2014;60(11):24866.
4. Baranoski S, Ayello EA. *Wound Care Essentials: Practice Principles*. 2nd ed. Lippincott Williams & Williams; c2008. Volume 2 2007. Chapter 14, Venous ulcers, lymphedema, and compression therapy; p. 281
5. Prakash AV, Davis MD. Contact dermatitis in older adults: a review of the literature. *AM J Clin Dermatol* 2010 11:373.

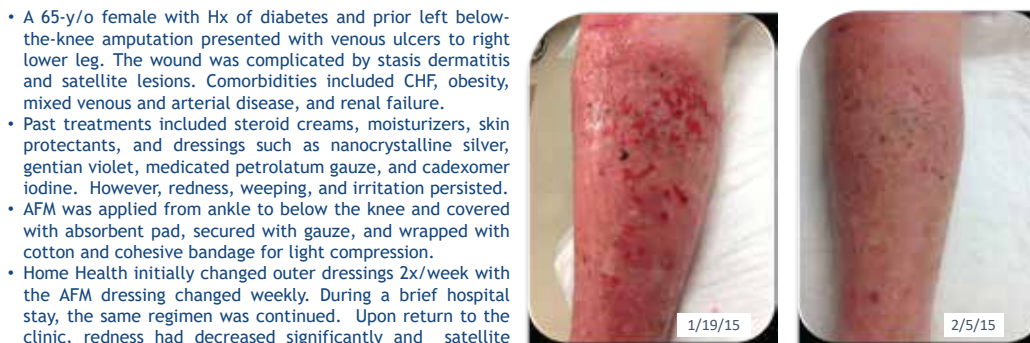
**TRITEC™ Silver (Milliken Healthcare Products, LLC; Spartanburg, SC)



- An otherwise healthy 94-y/o male presented with circumferential, diffuse venous ulcerations of right lower leg. Over the past 4 years, cadexomer iodine, gentian violet, and nanocrystalline silver dressings were used without consistent sustained results. Patient had frequent episodes of pruritus, weeping, and tenderness of the periwound. Due to the large surface area and heavy drainage, dressing changes were frequent (3x/wk), labor intensive, and painful.
- After one week with AFM, drainage had minimized, wounds decreased in size, and stasis dermatitis improved.
- After one month, many satellite lesions had healed, periwound tissue had improved, and drainage had decreased significantly. Dressing changes are now weekly. Patient reports decreased pain and improved quality of life.



- A 73-y/o male with ulcerations to his right foot and lower leg was being considered for amputation. Edema, erythema, and gross maceration were noted. Wound healing was complicated by tobacco abuse, obesity, DM, CHF, and venous insufficiency.
- AFM was applied to foot, between toes, and lower leg. Gauze was added between toes. Outer dressings consisted of absorbent pad, gauze, and bulky wrap with no compression. Home Health changed the outer dressings twice a week.
- After one month, the lower leg wound had resolved. The foot wounds required weekly selective debridement and dressing changes. In two months, wounds to the foot and toes had healed. Amputation was avoided.



- A 65-y/o female with Hx of diabetes and prior left below-the-knee amputation presented with venous ulcers to right lower leg. The wound was complicated by stasis dermatitis and satellite lesions. Comorbidities included CHF, obesity, mixed venous and arterial disease, and renal failure.
- Past treatments included steroid creams, moisturizers, skin protectants, and dressings such as nanocrystalline silver, gentian violet, medicated petrolatum gauze, and cadexomer iodine. However, redness, weeping, and irritation persisted.
- AFM was applied from ankle to below the knee and covered with absorbent pad, secured with gauze, and wrapped with cotton and cohesive bandage for light compression.
- Home Health initially changed outer dressings 2x/week with the AFM dressing changed weekly. During a brief hospital stay, the same regimen was continued. Upon return to the clinic, redness had decreased significantly and satellite lesions had resolved.

TRITECS21R01