

Investigating the Use of a Moisture Management Dressing for Tracheostomy Sites

Background

Tracheostomies are among the most common surgical procedures in North America, with over 150,000 performed each year.¹ Tracheostomies put patients at high risk for inpatient and outpatient complications, as well as for 30-day hospital readmissions.² Frequent complications include delayed healing and skin breakdown from excess peristomal moisture. The effective management of peristomal moisture has been shown to prevent both skin damage and infection,³ but continues to be difficult to achieve.

Objectives

The UMMC Wound, Ostomy, and Continence nursing department has observed peristomal skin breakdown associated with tracheostomies when using traditional dressings to manage the copious (often highly viscous) moisture. Dressings incorporating Active Fluid Management (AFM) technology have been shown to manage excessive levels of exudate in lower extremity venous leg ulcers resulting in maceration reduction and more healthy skin around the wound.⁴ This prospective study aimed to determine if AFM technology could be used to effectively manage the moisture associated with the surgical tracheostomy wounds.

Methods

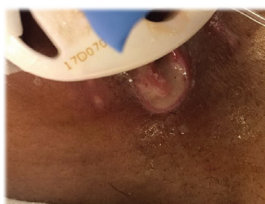A dressing with AFM technology was applied directly to the skin around the tracheostomy cannula of three patients. A secondary gauze dressing was placed over the study dressing to serve as a reservoir for excess exudate. Both the study dressing and the secondary dressing were placed beneath the trach flange and were changed daily.

References

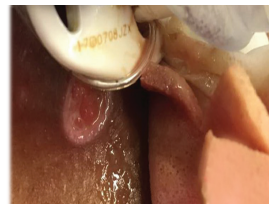1. Syeda S, Wiener R. National trends in the utilization of tracheostomy among United States adults, 1997-2008. Poster presented at: Quality Improvement: Using Research Methods, Clinical Support Tools and Teamwork to Improve Assessment and Treatment of Lung Diseases, May 16, 2011, Denver, CO
2. Spataro E, Durakovic N, Kallogeris D, Nussebaum B. Complications and 30-day hospital readmission rates and patients undergoing tracheostomy. *Laryngoscope*. 2017 May 23. doi: 10.1002/lary.26668.
3. Morris LL, Whitmer A, McIntosh E; Tracheostomy care and complications in the Intensive Care Unit. *Critical Care Nurse*. 2018; 88: 18-80
4. Vlad L, Farra CL, Barzkar H, Pestano IA, Molnar JA. Pilot Study Investigating the use of an exudate management dressing under compression for the treatment of venous leg ulcers. Poster presented at: SAWC April 2017, San Diego, CA

Patient 1

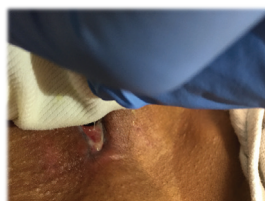Day 1



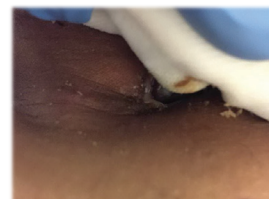Day 3



Day 18

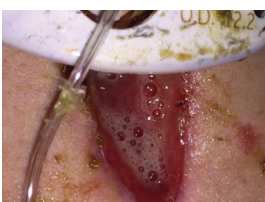


Day 35

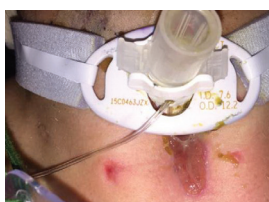

Patient 2

Day 1



Day 7



Outcomes

Daily assessments of the surgical wound and peristomal skin were conducted for each patient.

Patient #1: 61 year old male with subdural hematoma who developed respiratory failure, in an inpatient setting, with #8 cuffed Shiley type tracheostomy in place for 11 days presented with copious drainage resulting in peristomal skin breakdown and delayed wound healing. Foam dressings failed to manage the excessive, viscous secretions. The patient was enrolled in the study and a dressing with AFM technology was applied and changed daily. After 2 weeks, the wound edges had contracted and the peristomal skin was healthy. Use of the dressing was continued through complete wound healing (35 days), and continued prophylactically for 1.5 weeks until discharged to rehab facility.

Patient #2: 19 year old male with shallow dive injury, in an inpatient setting, with a #8 Shiley type tracheostomy in place for 17 days presented with copious drainage resulting in peristomal skin breakdown and delayed wound healing. The patient was enrolled in the study and a dressing with AFM technology was applied and changed daily. After only 6 days in the study, the wound edges had contracted, the peristomal skin was healthy and the AFM dressing was discontinued.

Patient #3: 63 year old female with a subarachnoid hemorrhage, in an inpatient setting, with a #8 Bivona TTS type tracheostomy in place for 9 days presented with erosion at the tracheostomy site due to moisture on the peristomal skin coupled with repetitive movement of the cannula. Within 5 days of being enrolled in the study, the erosion was reversed and tissue regrowth was observed.

Practice Recommendation

Based on these preliminary clinical assessments, we recommend a protocol that includes the use of a dressing with AFM technology to manage moisture associated with tracheostomies to minimize 1) peristomal skin complications and 2) delayed wound healing. Furthermore, the AFM technology may also be used prophylactically to prevent moisture-associated peristomal skin damage. Additional studies are recommended to assess the impact of this protocol for a larger patient population and to determine the impact on 30-day hospital readmission rates.