

# Antimicrobial Fluid Management Dressing Case Study

<sup>1</sup>Becky Greenwood BSN, RN, WOCN; <sup>2</sup>Annette Gwilliam BSN, RN, CWON, ACHRN

<sup>1</sup>Intermountain Healthcare, Home Health & Hospice, Salt Lake City, UT; <sup>2</sup>Intermountain Healthcare, Utah Valley Wound Clinic, Provo, UT

## BACKGROUND

Chronic wounds impose a significant and often underappreciated burden to the individual, the healthcare system and society as a whole.<sup>1</sup>

“A hard-to-heal wound has been defined as one that fails to heal with standard therapy in an orderly and timely manner. This definition applies equally to both acute and chronic wounds and is independent of the wound type and etiology.”<sup>2</sup>

Effective management of exudates, infections and complex tissue growth in a variety of wounds is still a major challenge for the researchers and wound dressing manufacturers have standardized the use of the product. We have seen an overall decrease in treatment time and decreased physician debridement time.<sup>3</sup>

## METHOD

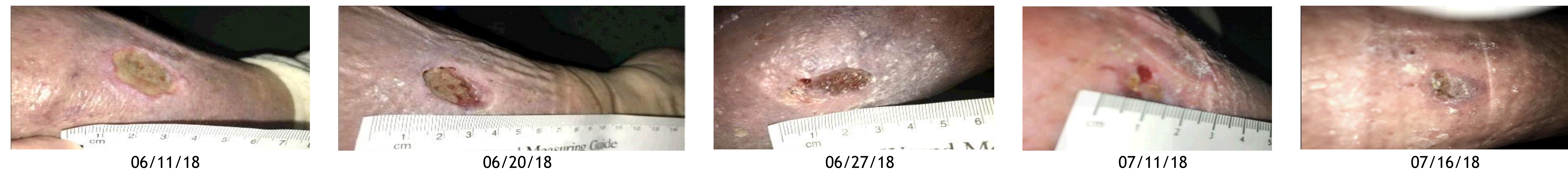Implementation of the treatment protocol using a dressing\* with active fluid management, coupled with silver technology. Treatment was provided in homecare, clinic and inpatient settings.

## CONCLUSION

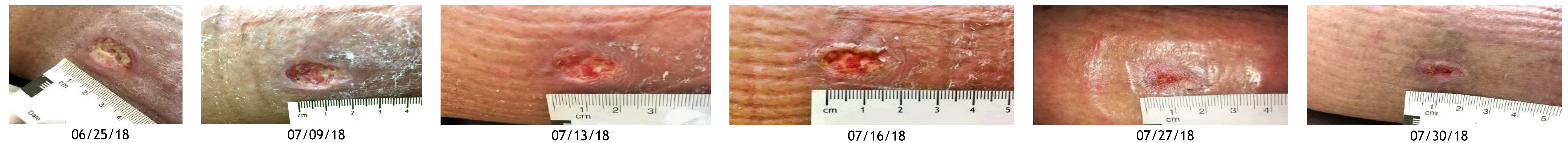
- Patient wound healing was accelerated. Number of nursing visits was decreased thus decreasing cost.
- Peri-wound skin was dryer
- Patients express high satisfaction and improved quality of life.

## RESULTS

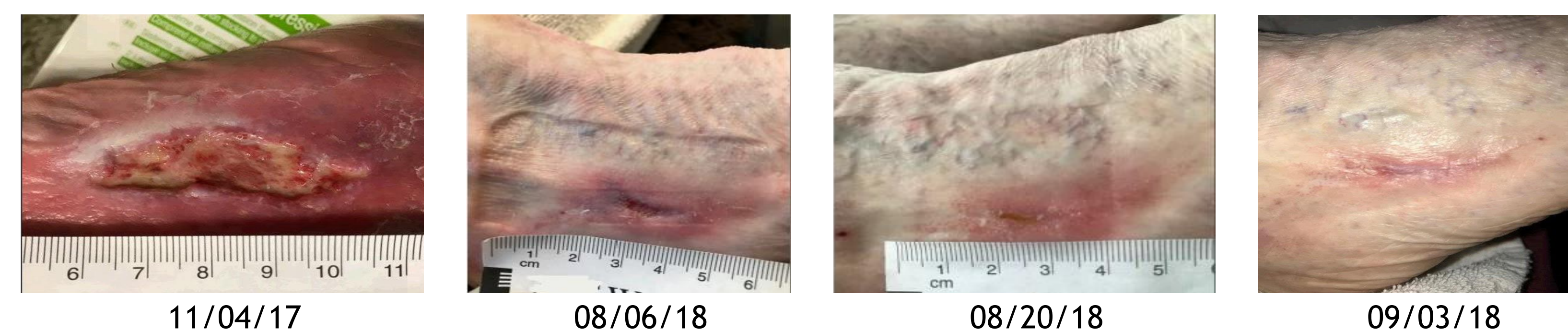
**Case #1.** 50 year old female with left side hemiplegia due to stroke in 2015. Wound started in Oct. 2017 from increased swelling and venous stasis. Blisters became ulcers. Patient had been going to wound clinic weekly for debridement. Wound care consisted of collagen as primary dressing, alginate and ABD pads as secondary dressing, and 2-layer compression wraps. Antimicrobial fluid management dressing with tubular elastic compression started 06/15/18. In 18 days the wound moved from 100% slough to epithelialized and the decreased in size from 4 cm<sup>2</sup> to 0.06 cm<sup>2</sup>. Patient and wound clinic are happy that the wound is almost healed in a month's time after 8 months of no progress.



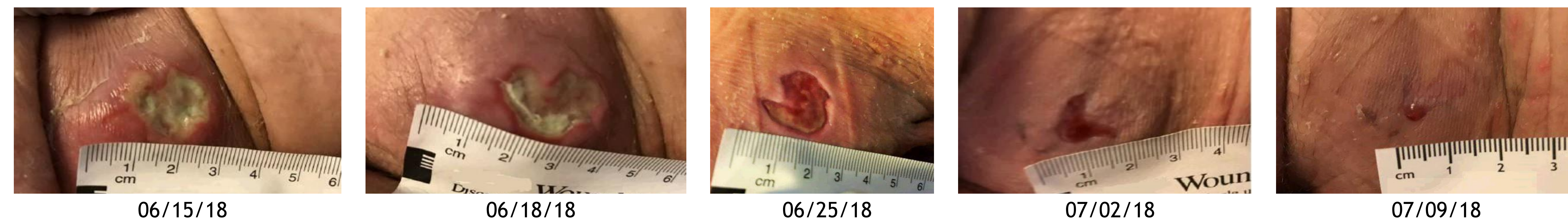**Case #2.** 80 year old male, COPD, venous stasis, lymphedema. Blisters turned to ulcers. The wound was first observed on 06/25/18 and treatment with collagen and 2-layer compression. Antimicrobial fluid management dressing with tubular elastic compression started on 07/09/18. In seven days, the wound decreased in size from 3.4 cm<sup>2</sup> to 0.15 cm<sup>2</sup>.



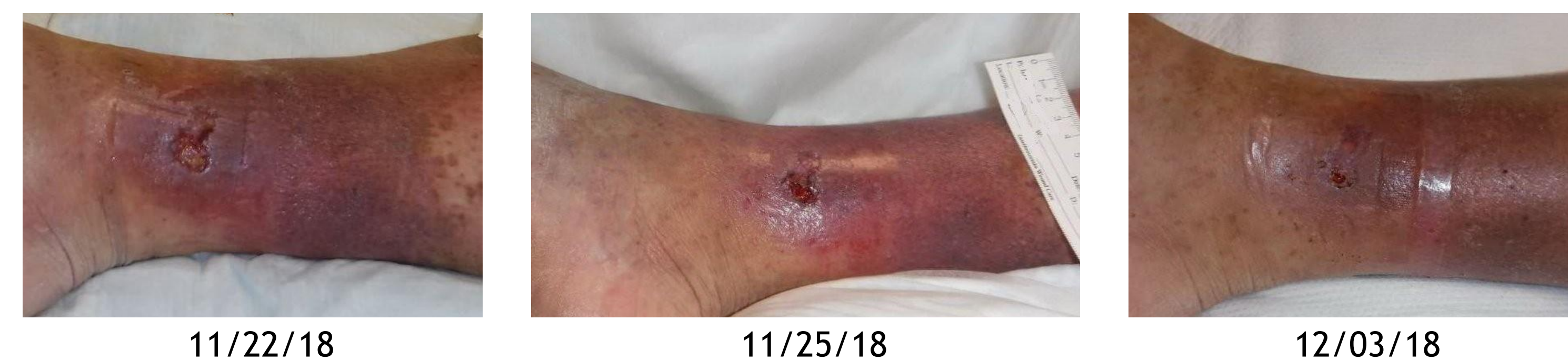**Case #3.** 74 year old female who had ganglion cyst removed about 10 years ago. She stated that every 2 years or so, her leg and foot would swell up and the site opened and created an ulcer. Patient confided how depressed she was that her wound was not healing and had been stagnant for the last 3 months. She thought the wound would never heal and wanted to give up going to wound clinic and having homecare visits. Antimicrobial fluid management dressing with tubular elastic compression started on 08/06/18. The wound was closed after 7 applications. The patient stated, "I am so happy and thankful to be part of this trial".



**Case #4.** 66 year old male with stage 3 pressure injury, which developed during a hospital stay. Wound care orders had been honey, alginate and foam dressing. Antimicrobial fluid management dressing started on 06/06/18. After one month and 10 applications, the wound decrease in size from 3 cm<sup>2</sup> to 0.09 cm<sup>2</sup>.



**Case #5.** 46 year old male with coronary artery disease, elevated liver enzymes, CHF, and chronic venous ulcer. Patient stated he had been going to wound clinic for about a year for treatment. After two applications of antimicrobial fluid management dressing, the wound decreased in size from 1.7 cm<sup>2</sup> to 0.09 cm<sup>2</sup>.



## FOOTNOTES

\*TRITEC™ Silver Dressing with Active Fluid Management® Technology, Milliken Healthcare Products LLC, Spartanburg, SC

Tubular elastic compression: EdemaWear Compression Stocking with Fuzzy Wale Compression, Compression Dynamics, Omaha, NE

## REFERENCES

1. Järbrink et al. Systematic Reviews (2016) 5:152 Prevalence and incidence of chronic wounds and related complications: a protocol for a systematic review.
2. Hard to Heal Wounds Made Easy. [www.woundsinternational.com/uploads/resources/8b209a588e74f81cc9dda6ed140a3c85.pdf](http://www.woundsinternational.com/uploads/resources/8b209a588e74f81cc9dda6ed140a3c85.pdf)
3. Sinha, Mukty. 2017. Advance measures and challenges of wound healing. Journal of pharmacology therapeutic research. Vol 2 Issue 1